



2025

KARNATAKA RADIOLOGY EDUCATION PROGRAM

CHIEF CAMPLAINTS

Name: Miss X

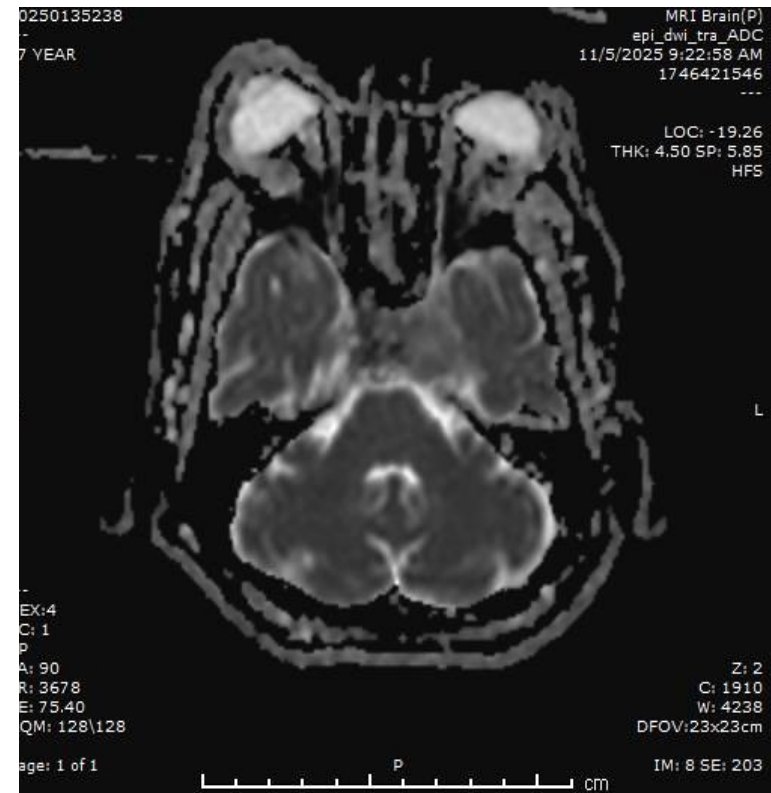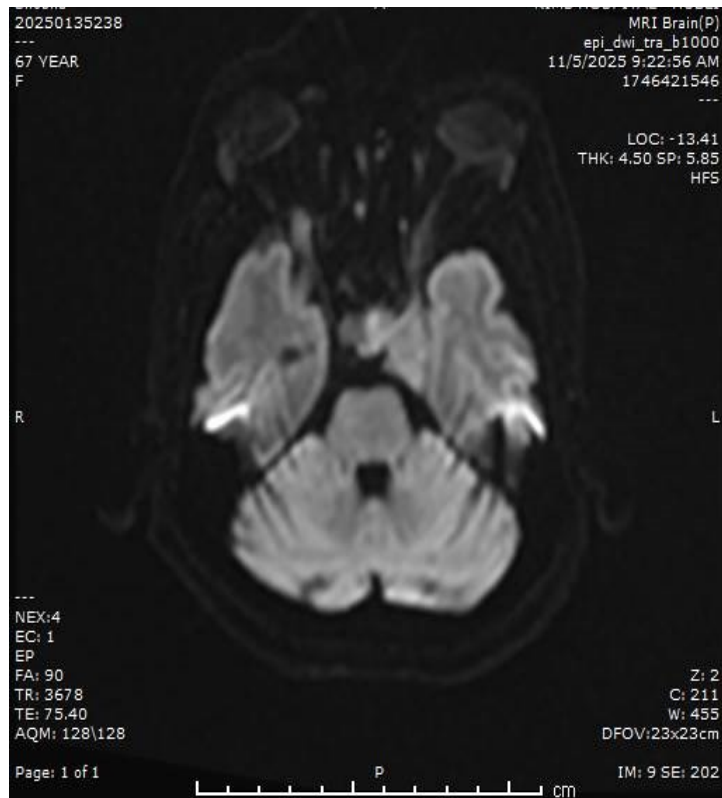
Age/sex: 33 year-female

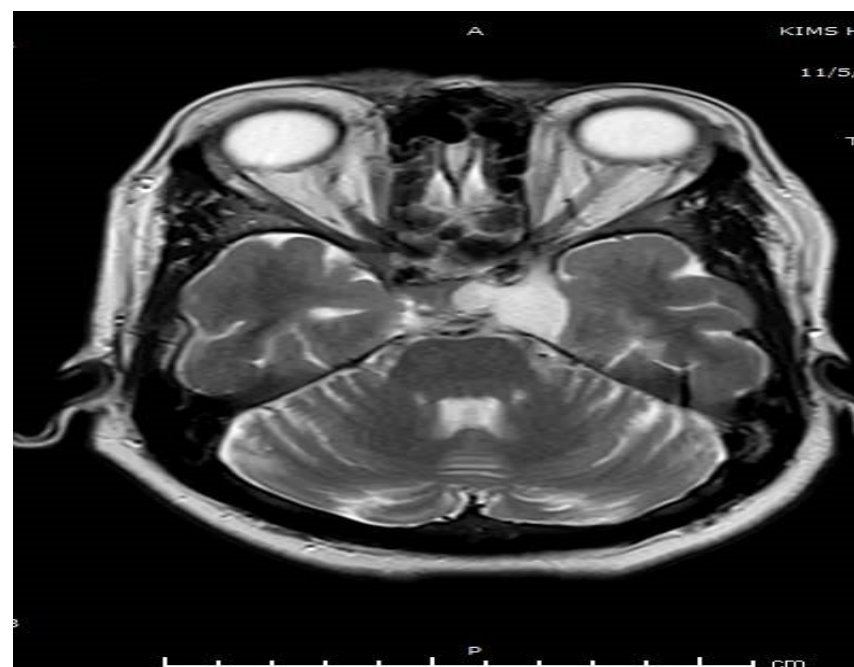
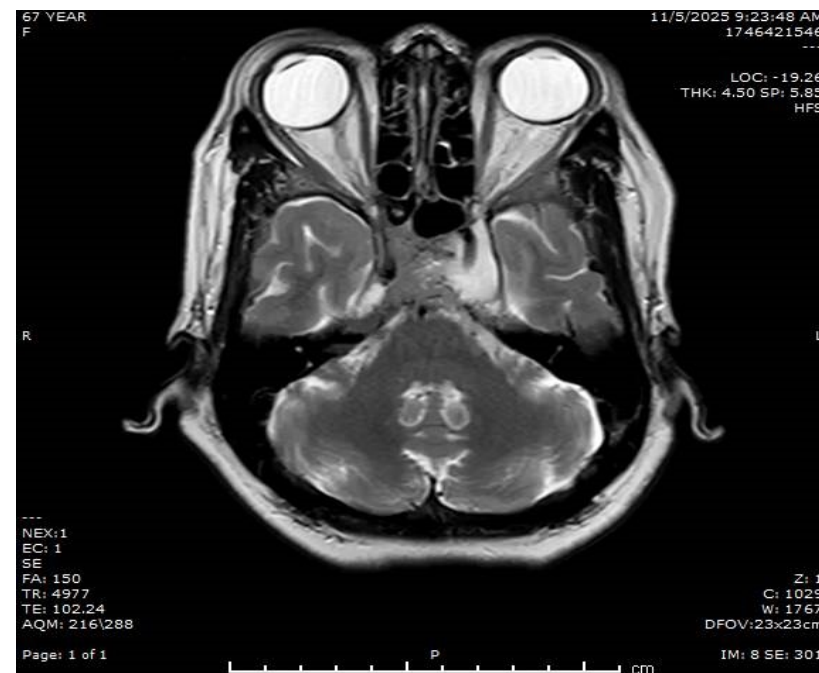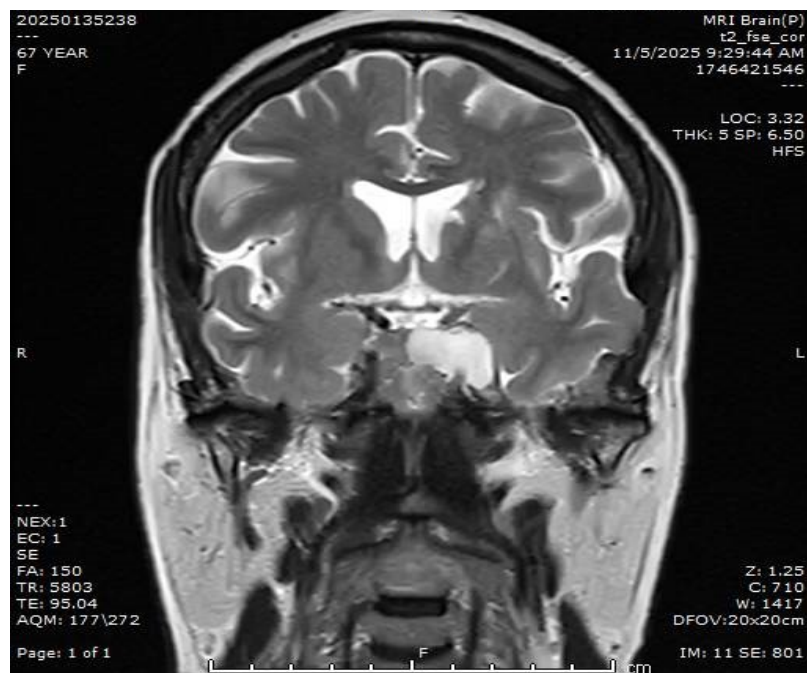
Place:hubballi

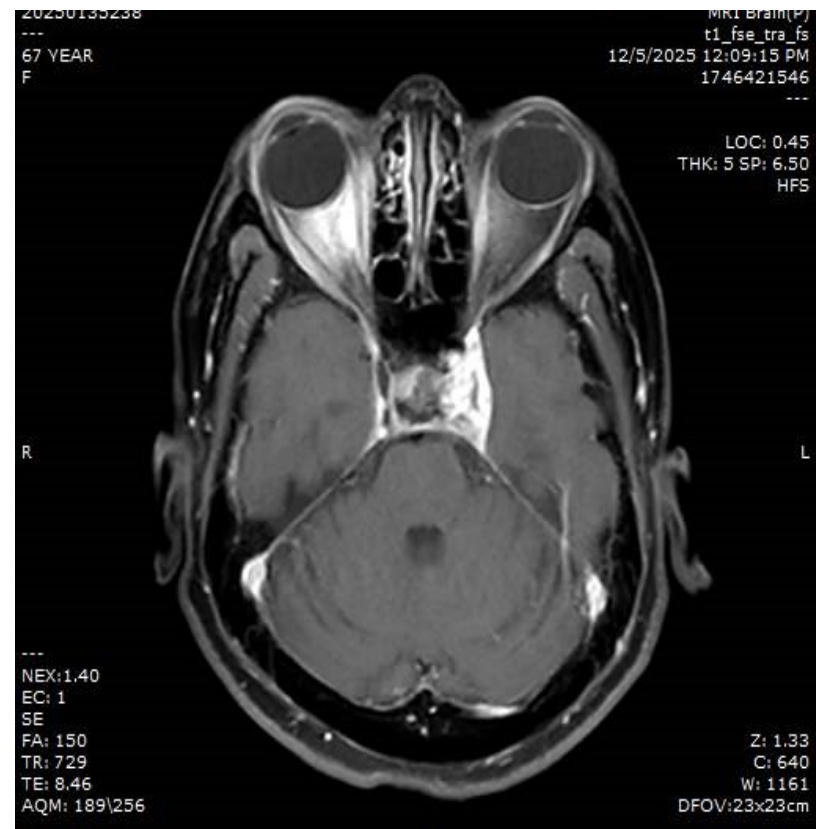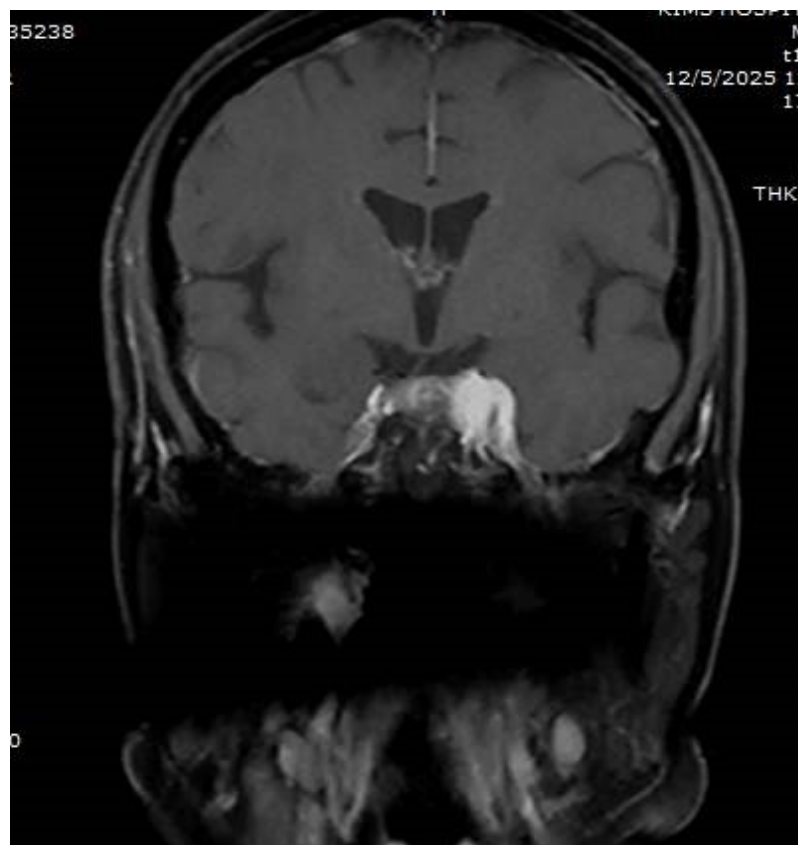
CHIEF COMPLAINTS:

Camplains of headache,diplopia ,visual disturbances since 3 months.

MRI







MRI FINDINGS

- **T2/FLAIR HYPERINTENSE LESION ALONG LEFT CAVERNOUS SINUS , SHOWS MILD DIFFUSION RESTRICTION ON POST CONTRAST SHOWS HOMOGENOUS ENHANCEMENT F/S/O LEFT CAVERNOUS SINUS LESION DD'S: 1. HEMANGIOMA V/S NERVE SHEATH TUMOR**

MENTORS

Dr.J.G Suttagatti

HOD AND PROFESSOR

DEPT OF RADIO DIAGNOSIS

KMCRI HUBLI

Dr.G C PATIL

PROFESSOR

DEPT OF RADIO DIAGNOSIS

KMCRI HUBLI

All Professor and teaching staff,dept of radiodiagnosis KMCRI HUBLI